

# The early results of our initial experience with robotic adrenalectomy

Cevher Akarsu<sup>1</sup>, Ahmet Cem Dural<sup>1</sup>, Burak Kankaya<sup>1</sup>, Muhammet Ferhat Çelik<sup>1</sup>, Osman Köneş<sup>1</sup>, Meral Mert<sup>2</sup>, Mustafa Uygur Kalaycı<sup>1</sup>, Halil Alış<sup>1</sup>

## ABSTRACT

**Objective:** Robotic adrenalectomy is one of the minimally invasive surgical methods gaining wide acceptance due to the three-dimensional imaging system and ergonomics of the equipment. We aimed to present the early data on patients who underwent robotic adrenalectomy due to adrenal masses in our hospital.

**Material and Methods:** The records of eight cases, in which a unilateral robotic trans-peritoneal adrenalectomy was conducted due to an adrenal mass between 2011 and 2013, have been evaluated. Demographic characteristics of cases, body mass index (BMI), American Society of Anesthesiologists (ASA) score, preoperative diagnosis, diameter and localization of the adrenal mass, operative time, blood loss, conversion rate to open surgery, morbidity and mortality rates, length of hospital stay, total hospital charges and postoperative pathologic results were considered.

**Results:** The female to male ratio was 6:2, the median age was 49.5 (26-71) and the median BMI was 29.7 (21.7-38.5). An adrenalectomy was performed in six cases for a right adrenal mass and in two cases for a left adrenal mass. The mean tumor diameter was 53.6 mm (20-90). The average surgical time (including docking) was 98 min. (55-175 min.) and the average blood loss was 50 mL. The only complication was a diaphragm injury which was repaired robotically. There were no conversions to traditional laparoscopic or open surgery and there have not been any mortality in the series. The median length of hospital stay was 4.1 days (range 2-11) and the average cost was 3617.12 TL (\$1808.56).

**Conclusion:** Robotic adrenalectomy is an effective and safe surgical alternative to laparoscopic adrenalectomy. However its high cost has emerged as its main disadvantage.

**Key Words:** Robotic adrenalectomy, minimally invasive surgery, laparoscopy, adrenal neoplasm

<sup>1</sup>Department of General Surgery, Bakırköy Dr. Sadi Konuk Training and Research Hospital, İstanbul, Turkey

<sup>2</sup>Department of Internal Medicine, Division of Endocrinology, Bakırköy Dr. Sadi Konuk Training and Research Hospital, İstanbul, Turkey

## Address for Correspondence Dr. Ahmet Cem Dural

Department of General Surgery, Bakırköy Dr. Sadi Konuk Training and Research Hospital, İstanbul, Turkey  
Phone: +90 212 414 71 59  
e-mail: cemdural@hotmail.com

Received: 12.07.2013  
Accepted: 08.12.2013

©Copyright 2014  
by Turkish Surgical Association  
Available online at  
www.ulusalcerahidergisi.org

## INTRODUCTION

After description of laparoscopic methods in adrenal surgery, the transperitoneal approach by Gagne (1) in 1992 and the retroperitoneal approach by Mercan (2), minimally invasive surgical techniques have been adopted, and evolution of these methods have continued with subsequent advances in technology.

It has been shown that laparoscopic adrenalectomy (LA) results in less postoperative period pain and decreases the need for analgesics, as well as a shorter length of hospital stay, shorter operative time, less cost, and better cosmetic results as compared to open adrenalectomy (OA) (1-5). For these reasons, LA has become the current standard method of treatment.

With the introduction of robotic surgery technology in many areas of surgery, the use of more ergonomic hand instruments, and the convenience they provided to the surgeon despite high costs, have made robotic adrenalectomy (RA) emerge as an alternative method to LA, and various RA techniques have been described (6, 7).

In our hospital, daVinci® SI robotic system is being used since 2009 (Figure 1), as until the end of 2012, 459 robotic surgeries have been performed, 41 of which were done by our General Surgery Clinics (Figures 2a and 2b). Most of the robotic procedures (74%, n=340) were performed by Department of Urology. Robotic systems is being applied to increasing number of patients, in a growing variety of applications in general surgery patients and in our department it is mainly applied in colorectal and upper gastrointestinal system surgery, bariatric surgery and solid organ surgery (8).

As of 2013, there are 3000 robotic systems throughout the world, and 18 of them are available in our country. Since our clinic is one of the first centers to use robotic surgery technology in our country, in this study we aimed to present our initial results of transperitoneal RA.

**MATERIAL AND METHODS**

Among patients who have been elected to undergo surgery due to an adrenal mass by the multidisciplinary endocrinology council between January 2011 and February 2013, eight patients in whom an RA was performed were identified. The demographic characteristics of cases, body mass index (BMI), American Society of Anesthesiologists (ASA) score, preoperative diagnosis, diameter and localization of the tumor, operative time, blood loss, conversion rate to open surgery, morbidity and mortality rates, length of hospital stay, total hospital char-

ges and postoperative pathologic results were retrospectively evaluated.

The multidisciplinary endocrinology council consisting of general surgery, endocrinology, pathology, radiology and nuclear medicine specialists evaluated all patients prior to surgery. All functional tests and magnetic resonance (MR) imaging were performed by the department of Endocrinology. Patients with preoperative manifestations of Cushing’s were operated under appropriate steroid treatment. Informed consent was obtained for the procedure and its potential complications from all patients undergoing robotic surgery.

All operations were done by the same surgeon, using daVinci® SI robotic surgical system (Intuitive Surgical™, Mountain View, CA, USA).

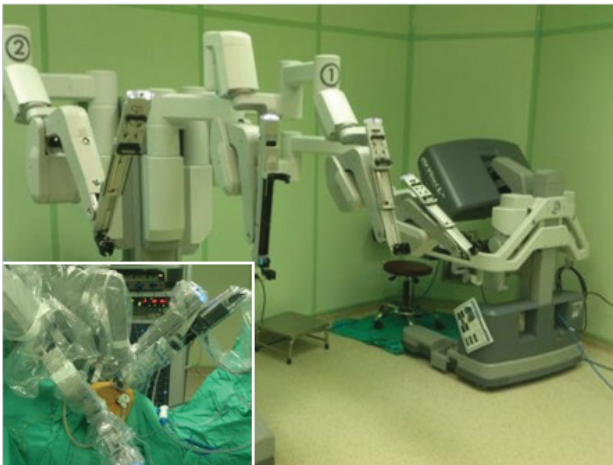

Figure 1. Robotic system operating table and tower

Patient preparation, positioning and port sites in robotic adrenalectomy are similar with the laparoscopic technique and in our department, surgery was performed in the standard lateral decubitus position. Following the creation of pneumoperitoneum, four ports were introduced. One of these ports were not attached to the robotic arm, a laparoscopic port was preferred so that the assistant can use standard laparoscopic instruments (aspirator, clip applier etc.). Although the location of this port, which is used to facilitate surgical manipulation, varied according to patient weight and anatomical structure, it was routinely placed at the most medial position for right RA and the most lateral for left RA.

A grasping instrument with bipolar cauterization capability, a robotic ultrasonic sealing and cutting device and a 30° camera were placed to the other three robotic arms. Following initial exploration with laparoscopic camera, the docking process was started.

The docking process is one of the most important stages of the operation. Reposition of port sites once the surgery begins is very difficult. According to the patient’s anatomy and position, the robot tower was brought towards the operating table from the ipsilateral shoulder, the robotic arms were angulated according to port sites, and the ports were docked.

In right robotic adrenalectomy cases, retraction of the liver was achieved with a 5 mm angulated retractor, 10 mm standard retractor or laparoscopic aspirator that was operated by the first assistant. The hepatic flexure was pulled down, the peritoneum was opened and the right adrenal gland was exposed by following landmarks (Figure 3).

In left robotic adrenalectomy cases, peritoneal dissection was done between the splenic flexure and the spleen and similarly, the left adrenal gland was exposed following landmarks. During dissection, a laparoscopic aspirator provided blunt counter-traction. In both right and left RA following identification of the adrenal vein, adrenalectomy was completed after the adrenal vein was first clipped and then cut, however sealing devices may also be preferred. In all the cases, the specimen was extracted within an endoscopic bag, and if required, the

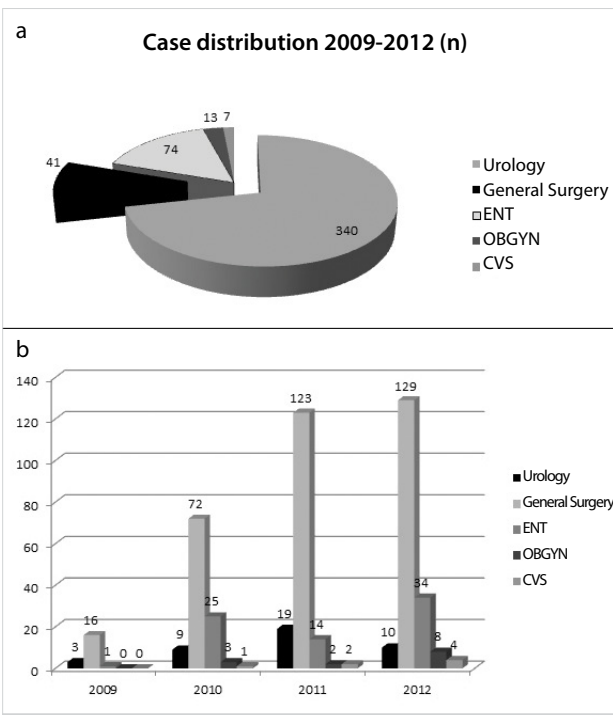


Figure 2a. Robotic case distribution according to departments b) Robotic case distribution according to years stratified by departments

port incision was extended according to the size of the mass for extraction. In our patients, surgical drains were not placed routinely but only in cases that the surgeon preferred. Following the removal of the specimen, ports were removed under direct camera vision and the operation was terminated after suturing these sites.

Postoperatively, all patients received a standard dose of analgesia and if they received preoperative steroids, the maintenance dose was continued. Follow-up evaluations were done in endocrinology and general surgery outpatient clinics at the first week after discharge.

### Statistical Analysis

Statistical Package for the Social Sciences (SPSS®) 17.0 for Windows (SPSS® Inc., Chicago, IL) was used for analysis. Values were stated as mean and median (minimum-maximum).

### RESULTS

Six patients were female (75%), and the mean age of patients was 49.5 (26-71). The mean BMI was 29.7 (21.7 to 38.5). The mass was located in the right adrenal gland in four patients (50%), and in the left adrenal gland in two patients (25%). In

two cases (25%), bilateral adrenal masses were present; in one patient, the mass on the right side was greater than the lesion on the left and in the other patient the mass on the right side was 9 cm and on Positron Emission Tomography (PET-CT) imaging showed a high FDG uptake. In both of these cases, a decision to perform right adrenalectomy was reached as per endocrinologist's suggestion.

In the preoperative function evaluation, four cases were detected as Cushing's clinical presentation. These cases were operated with perioperative steroid treatment as arranged by endocrinology. Including two patients with bilateral masses right adrenalectomy was performed in six patients (75%), and in two patients left (25%) adrenalectomy was done.

The mean diameter of the mass was 53.6 mm (20-90). The mean operative time (including the docking time) was 98 min (55-175) and the average blood loss was 50 mL. None of the cases required conversion to either standard laparoscopy or open surgery. Histopathological examination of the cases, including cases of suspected malignancy, revealed adrenal cortical adenoma. As a complication, in one patient the diaphragm was injured during right adrenalectomy (12.5%) that was repaired robotically. There was no mortality. The mean length of hospital stay was 4.1 days (2-11) and the average cost was calculated as 3,617.12 £ (1,808.56 \$) (Table 1).

### DISCUSSION

Since the 1990s open adrenalectomy has been replaced with LA and the implementation of minimally invasive surgery in adrenal gland surgery has gained significant momentum (1, 2). Currently, LA has become a standard surgical method in many centers (4, 5). Guerrieri et al. (9) indicated the learning curve for the right and left sided LA as 30 and 40 cases, respectively. Nevertheless, due to the low incidence of cases, the

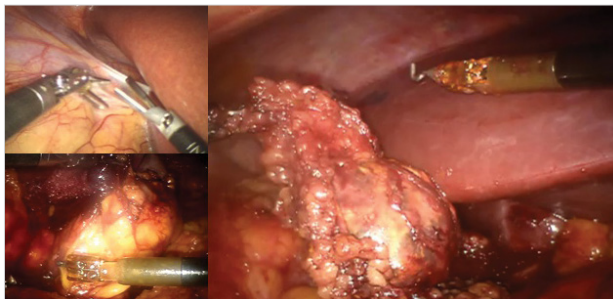


Figure 3. Right robotic adrenalectomy stages

Table 1. Demographic properties and surgical findings

Case (Year)	Age	Gender	BMI	ASA Score	Mass Function	Mass Location	Mass size (mm)	Surgery	Docking duration (min)	Total operation duration (min)	Complication	Length of stay (day)	Pathology	Cost (TL)
1 (2011)	34	F	21.77	2	Cushing <sup>†</sup>	Right	20	Right RLTA	40	175	-	2	ACA	2.406
2 (2011)	71	F	25.08	2	Cushing <sup>†</sup>	Left	39	Left RLTA	25	115	-	2	ACA	4.841
3 (2012)	40	F	25.71	1	NF	Right	68,7	Right RLTA	30	110	-	3	ACA	5.251
4 (2012)	43	F	30.47	2	NF	Right	41,6	Right RLTA	25	80	-	3	ACA	2.870
5 (2012)	54	M	28.88	4	Cushing <sup>†</sup>	Bilateral	51,3	Right RLTA*	30	110	-	5	ACA	3.027
6 (2013)	61	M	34.29	2	Cushing <sup>†</sup>	Bilateral	90	Right RLTA**	20	65	-	11	ACA	4.530
7 (2013)	26	F	33.14	3	NF	Right	73,8	Right RLTA	20	75	DI	4	ACA	2.774
8 (2013)	67	F	38.57	3	NF	Left	44,4	Left RLTA	15	55	-	3	ACA	5.238

BMI: Body Mass Index; ASA: American Society of Anesthesiology; NF: non-functioning; RLTA: robotic lateral transabdominal adrenalectomy; DI: diaphragma injury; ACA: adrenocortical adenoma

<sup>†</sup>Operation under corticosteroid treatment

\*Right adrenal gland significantly enlarged on MRI (left adrenal gland dimension 2 cm)

\*\*Increased FDG uptake in the right adrenal gland on PET-CT

<sup>‡</sup>Cost; calculated with the assumption that reusable instruments of robotic arms are used in 10 cases

anatomical localization of the adrenal gland and their special vascularization, adrenal surgery is a surgical procedure that is only performed by experienced surgeons.

As in all other laparoscopic procedures, laparoscopic adrenalectomy also has the following disadvantages; rigidity of the available hand instruments, a two-dimensional display system that does not allow perception of depth, failure to obtain a stable camera image, requirement of one or more assistants due to the ability to use only two arms, negative effects of tremor due to the inconvenient surgeon position, and the long learning curve (10, 11).

With the development of robotic technology, RA has been introduced to adrenal surgery. The RA technique precludes a large portion of LA's disadvantages and its learning curve requires less than 20 cases in surgeons with experience in laparoscopic surgery, and is becoming an increasingly common technique worldwide (12). The main factors in effective in the spread of robotic systems are appropriate flexible ergonomic hand tools integrated into its arm, possibility to use more than two arms, achievement of a stable and three-dimensional image and creation of a more comfortable surgical environment for the surgeon (3, 7, 13-15). Robotic adrenalectomy provides a single working field and since it does not require positional docking changes, the aforementioned advantages are felt at the maximum level. That is why although RA is safer but more costly as compared to LA, particularly due to the comfort it offers to the surgeon, it is preferred with increasing frequency in hospitals that have the opportunity to work with robotic systems (10). As the number of cases increase, the docking process is shortened, and the operative time significantly decreases with adaptation to the device and skills achieved through the learning curve (10, 16).

In the literature, it has been reported that RA is similar to LA in terms of operative time, length of hospital stay and postoperative pain (12). In addition, studies indicating that in patients with high BMI and those with large tumors RA is more successful have also been published (7).

The most important disadvantage of robotic surgery is still its cost. In studies on overall cost, RA is cheaper than OA and costs

slightly more than LA (15, 17-19). However, it has been reported that the cost is reduced in large centers, if high number of robotic procedures are carried out by various departments (17, 19). In general, other disadvantages of robotic surgery can be listed as damaging tissues by robotic arms that have a high energy since the surgeon cannot touch the ports and might make an uncontrolled move, the difficulty in changing patient position and port sites after docking, the ports being larger than the laparoscopic ones, the lack of angulation of instruments like sealing devices that provide coagulation, clip applicator, and bipolar cautery and difficulty in performing multiple intra-abdominal procedures in different quadrants (20). However, developments in robotics technology and hand instruments are rapidly progressing and those problems, especially tactile feedback, are likely to be solved in the near future (21). The wrong positioning of ports may considerably complicate hemostasis and dissection as compared to laparoscopic surgery (12).

In our department, before the application of robotic surgery, LA was performed on 20 patients. Six of the eight patients in our series had a right adrenalectomy, and two underwent left adrenalectomy. In the first case, the operation time including docking was 175 min, whereas in the last case it was 55 min. Along with the increase in the number of cases in our series, the operative time decreased in a manner consistent with the literature. The mean operative time in our series was 98 min that is shorter than the literature (16, 20, 22). This shorter duration of operation can be explained by the excess number of laparoscopic cases in all patients in our clinic and the experience in advanced laparoscopic surgery.

The conversion rate to open surgery is reported as 0-6% in the literature and in our series conversion to standard laparoscopy or open surgery was not required (7, 12, 17). The main reasons for conversion to open surgery are stated as insufficient exposure of the surgical field, technical problems and requirement of excessive dissection due to excess fat tissue in patients (22).

The mortality rate has been reported as 2.4% by Giulianotti et al. (7), but in our case series mortality was not observed parallel to the literature (15, 16, 18, 20, 22-24). In the literature, the

Table 2. Literature results regarding RA

Author, Year	Case number (n)	Operation time (min)	Surgical technique	Conversion to standard laparoscopy or open surgery (%)	Morbidity (%)	Mortality (%)	Length of hospital stay (day)
Morino et al. (17), 2004	10	169 (136-215)	RLTA	40	-	-	5.7 (4-9)
Winter et al. (15), 2006	30	185 (130-295)	RLTA	5	10	-	2 (1-5)
Brunaud et al. (12), 2008	100	99 (40-275)	RLTA	5	10	-	6.4±3.0*
Berber et al. (24), 2010	8	214.8±40.8*	RPRA	-	-	-	1
Giulianotti et al. (25), 2011	42	118±46*	RLTA	-	2.4	2.4	4 (1-22)
D'Annibale (16), 2011	30	200 (180-255)	RLTA	3.3	10	-	5 (2-11)
Aksoy et al. (22), 2012	42	186.1±12.1*	RPRA	-	4.7	-	1.3±0.1*

\*Values are stated as mean±SD. RLTA: Robotic lateral transabdominal adrenalectomy; RPRA: robotic posterior retroperitoneal adrenalectomy



complication rate has been reported to be below 5% and similar rates is expected to be achieved with increasing number of cases and experience (Table 2) (7, 18, 20, 22-25).

Popularity of robotic surgery is increasing all over the world, and many authors emphasize the fact that in addition to the comfort and advantages the device offers to the surgeon, the financial burden of research and development of this superior technology and the lack of competition within this field increase the cost of spare parts and maintenance, therefore significantly increasing overall cost. This cost reflects to the patient or insurance company, and inevitably causes a burden on the public health system.

However, as mentioned in publications that compare surgical methods (15, 17, 21), it is particularly emphasized that in centers where different branches use the robotic system in high volume, the costs of spare parts and maintenance is decreased to a more acceptable level as well as decreasing the general cost by utilization of the robotic system at maximum efficiency.

Indeed, evaluation of number of days the system was used/ days of active work according to the number of cases performed in our hospital by various departments other than general surgery in 2012 (n=185), it is seen that an optimum level has been reached. For this reason, it is expected that the difference in cost as compared to the already existing conventional laparoscopic surgery will decrease.

On the other hand, the possibility of lowering the costs to an acceptable level by greater technological competition is promising for the future of robotic surgery.

### Study Limitations

Patients presenting with adrenal mass are rare, and they usually do not present to general surgery clinics primarily. In our hospital, a multidisciplinary platform was developed including endocrinology and nuclear medicine specialists and the number of cases requiring surgery has increased in time.

### CONCLUSION

Robotic adrenalectomy is a superior minimally invasive technique especially in single area surgery. It is an alternative to laparoscopic adrenalectomy, has ergonomic advantages, and is a safe and effective surgical option. Although the major drawback is its high cost, utilization of robotic systems in common use by multiple departments and high patient volume of the hospital are factors that can reduce the cost.

The robotic system that is highly suitable for single area surgery is expected to be cleared from its hardware and software disadvantages in the near future with technological advances, including tactile feedback. In addition, the existing system is likely to be an exquisite alternative technique for adrenal surgery in the future by its programmatically facilitated application as clashing of instruments through a single port is prevented.

**Ethics Committee Approval:** Due to the retrospective design, ethical approval was not obtained.

**Informed Consent:** Written informed consent was obtained from patients who participated in this study.

**Peer-review:** Externally peer-reviewed.

**Author Contributions:** Concept - H.A., C.A.; Design - A.C.D., C.A.; Supervision - M.M., M.U.K., O.K.; Data Collection and/or Processing - B.K., M.F.Ç., M.M.; Analysis and/or Interpretation - O.K., M.F.Ç., M.M., M.U.K.; Literature Review - B.K., M.F.Ç., O.K.; / Writer - C.A., A.C.D.; Critical Review - H.A., M.U.K.; Other - H.A., B.K., A.C.D., C.A.

**Acknowledgement:** The authors would like to thank general surgery residents Cemal Deniztaş, M.D., Mahmut Doğan, M.D., Özlem Soyluk Selçukbiricik, M.D. and Pınar Karakaya, M.D. , from Div. of Endocrinology, Filiz İslim, M.D., F. Aysun Erbahçeci Salık, M.D., from Dept. of Interventional Radiology and Hürriyet Turgut, M.D. from Dept. of Pathology for their contributions to multidisciplinary management of the cases.

**Conflict of Interest:** No conflict of interest was declared by the authors.

**Financial Disclosure:** The authors declared that this study has received no financial support.

### REFERENCES

1. Gagner M, Lacroix A, Bolte E. Laparoscopic adrenalectomy in Cushing's syndrome and pheochromocytoma. *NEJM* 1992; 327: 1033. [\[CrossRef\]](#)
2. Mercan S, Seven R, Ozarmagan S, Tezelman S. Endoscopic retroperitoneal adrenalectomy. *Surgery* 1995; 118: 1071-1076. [\[CrossRef\]](#)
3. Heslin MJ, Winzeler AH, Weingarten JO, Diethelm AG, UristMM, Bland KI. Laparoscopic adrenalectomy and splenectomy are safe and reduce hospital stay and charges. *Am Surg* 2002; 69: 377-381.
4. Park HS, Roman SA, Sosa JA. Outcomes from 3144 adrenalectomies in the United States: which matters more, surgeon volume or specialty? *Arch Surg* 2009; 144: 1060-1067. [\[CrossRef\]](#)
5. Murphy MM, Witkowski ER, Ng SC, McDade TP, Hill JS, Larkin AC, et al. Trends in adrenalectomy: a recent national review. *Surg Endosc* 2010; 24: 2518-2526. [\[CrossRef\]](#)
6. Morris LF, Perrier ND. Advances in robotic adrenalectomy. *Curr Opin Oncol* 2012; 24: 1-6. [\[CrossRef\]](#)
7. Giulianotti PC, Buchs NC, Addeo P, Bianco FM, Ayloo SM, Caravaglios G, et al. Robot-assisted adrenalectomy: a technical option for the surgeon? *Int J Med Robot* 2011; 7: 27-32. [\[CrossRef\]](#)
8. Alış H, Gönenç M, Deniztaş C, Kapan S, Turhan AN, Aygün E. Robotic abdominal surgery: Initial experience from a single center. *Ulusal Cer Derg* 2011; 27: 90-93.
9. Guerrieri M, Campagnacci R, De Sanctis A, Baldarelli M, Coletta M, Perretta S. The learning curve in laparoscopic adrenalectomy. *J Endocrinol Invest* 2008; 31: 531-536.
10. Brunaud L, Ayav A, Zarnegar R, Rouers A, Klein M, Boissel P, et al. Prospective evaluation of 100 robotic-assisted unilateral adrenalectomies. *Surgery* 2008; 144: 995-1001. [\[CrossRef\]](#)
11. Hyams ES, Stifelman MD. The role of robotics for adrenal pathology. *Curr Opin Urol* 2009; 19: 89-96. [\[CrossRef\]](#)
12. Brunaud L, Bresler L, Ayav A, Zarnegar R, Raphoz AL, Levan T, et al. Robotic-assisted adrenalectomy: what advantages compared to lateral transperitoneal laparoscopic adrenalectomy? *Am J Surg* 2008; 195: 433-438. [\[CrossRef\]](#)

13. Hubens G, Ysebaert D, Vaneerdeweg W, Chapelle T, Eyskens E. Laparoscopic adrenalectomy with the aid of the AESOP 2000 robot. *Acta Chir Belg* 1999; 99: 125-129.
14. Horgan S, Vanuno D. Robots in laparoscopic surgery. *J Laparosc Adv Surg Tech* 2001; 11: 415-419. [\[CrossRef\]](#)
15. Winter JM, Talamini MA, Stanfield CL, Chang DC, Hundt JD, Dackiw AP, et al. Thirty robotic adrenalectomies: a single institution's experience. *Surg Endosc* 2006; 20: 119-124. [\[CrossRef\]](#)
16. D'Annibale A, Lucandri G, Monsellato I, de Angelis M, Pernazza G, Alfano G, et al. Robotic adrenalectomy: technical aspects, early results and learning curve. *Int J Med Robotics Comput Assist Surg* 2012; 8: 483-490. [\[CrossRef\]](#)
17. Morino M, Beninca` G, Giraudo G, Del Genio GM, Rebecchi F, Garone C. Robot-assisted vs laparoscopic adrenalectomy: a prospective randomized controlled trial. *Surg Endosc* 2004; 18: 1742-1746. [\[CrossRef\]](#)
18. Agcaoglu O, Aliyev S, Karabulut K, Siperstein A, Berber E. Robotic vs laparoscopic posterior retroperitoneal adrenalectomy. *Arch Surg* 2012; 147: 272-275. [\[CrossRef\]](#)
19. Brunaud L, Germain A, Zarnegar R, Cuny T, Ayav A, Bresler L. Robot-assisted adrenalectomy. *Surg Laparosc Endosc Percutan Tech* 2011; 21: 248-254. [\[CrossRef\]](#)
20. Pineda-Solis K, Medina-Franco H, Heslin MJ. Robotic versus laparoscopic adrenalectomy: a comparative study in a high-volume center. *Surg Endosc* 2013; 27: 599-602. [\[CrossRef\]](#)
21. Bark K, McMahan W, Remington A, Gewirtz J, Wedmid A, Lee DI, et al. In vivo validation of a system for haptic feedback of tool vibrations in robotic surgery. *Surg Endosc* 2013; 27: 656-664. [\[CrossRef\]](#)
22. Aksoy E, Taskin HE, Aliyev S, Mitchell J, Siperstein A, Berber E. Robotic versus laparoscopic adrenalectomy in obese patients. *Surg Endosc* 2013; 27: 1233-1236. [\[CrossRef\]](#)
23. Nordenstrom E, Westerdahl J, Hallgrimsson P, Bergenfelz A. A prospective study of 100 robotically-assisted laparoscopic adrenalectomies. *J Robotic Surg* 2011; 5: 127-131. [\[CrossRef\]](#)
24. Berber E, Mitchell J, Milas M, Siperstein A. Robotic posterior retroperitoneal adrenalectomy: operative technique. *Arch Surg* 2010; 145: 781-784. [\[CrossRef\]](#)
25. Giulianotti PC, Buchs NC, Addeo P, Bianco FM, Ayloo SM, Caravaglios G, et al. Robot-assisted adrenalectomy: a technical option for the surgeon? *Int J Med Robot* 2011; 7: 27-32. [\[CrossRef\]](#)